



Intubation precautions in a pediatric patient with severe COVID-19

Robert Shaw^{a, **}, Nathaniel Tighe^a, Kirsten C. Odegard^a, Peta Alexander^{b, c}, Sitaram Emani^d, Koichi Yuki^{a, *}

^a Department of Anesthesiology, Critical Care and Pain Medicine, Boston Children's Hospital, USA

^b Department of Cardiology Boston Children's Hospital, USA

^c Department of Pediatrics Harvard Medical School, USA

^d Department of Surgery, Cardiac Surgery, Boston Children's Hospital, USA

ARTICLE INFO

Keywords:

COVID-19

Lung injury

Surgery

ABSTRACT

We present the case of a child diagnosed with COVID-19 soon after open-heart surgery who required an urgent second surgery. The patient suffered from severe COVID-19 disease. The utility of preoperative COVID-19 testing, determination of recovery by an array of inflammatory markers and perioperative management are described.

1. Introduction

Coronavirus disease 19 (COVID-19) is caused by a novel coronavirus SARS-CoV-2, which initially occurred in Wuhan, China in December 2019 and subsequently spread to approximately 200 countries. The virus primarily affects the respiratory system, although other organ systems may also be involved. The respiratory presentations of COVID-19 are heterogenous ranging from minimal symptoms to significant hypoxia with acute respiratory distress syndrome (ARDS). The fact that a subset of patients manifest minimal symptoms complicates the attenuation of its spread. Current medical management is largely supportive without targeted therapies. This has led many countries to implement social distancing and lockdown. Amidst the pandemic of COVID-19, operating room (OR) management of patients with COVID-19 likely increases. We present a case of a pediatric patient who was diagnosed with COVID-19 soon after open-heart surgery who required an urgent second surgery. The HIPAA authorization has been obtained from his parent.

2. Case report

A 3-year-old male with heterotaxy, double outlet right ventricle with

D-malposed great arteries, subpulmonary ventricular septal defect (VSD), type A interrupted aortic arch, hypogammaglobulinemia immunodeficiency treated with intravenous immunoglobulin therapy, and chronic lung disease with previous tracheostomy (now decannulated) presented for biventricular repair in the setting of persistent cyanosis after multiple palliative cardiac interventions. The biventricular repair occurred amidst the early phase of the local COVID-19 pandemic. Our institution had implemented policies regarding safe care of all patients who qualified for urgent or emergent surgery during the imposed restriction of routine services. At the time of this surgery, routine COVID-19 preoperative testing had not been implemented. Potential asymptomatic carrier status of pediatric patients was managed with personal protective equipment (PPE) precautions for healthcare providers and appropriate barriers for intubation (Fig. 1) to minimize risk of aerosolization for all procedures. The surgery consisted of an arterial switch, pulmonary artery plasty, VSD closure with baffling of the left ventricle to the aorta, and fenestrated atrial septal defect (ASD) closure. Post-operative imaging was reassuring for adequate repair, but he came off cardiopulmonary bypass in complete heart block requiring pacing for atrioventricular synchrony with temporary pacing wires. He required minimal inotropic support and was extubated to nasal cannula on post-operative day (POD) #3. Early post-extubation hypoxia and

Abbreviations: COVID-19, Coronavirus disease 19; ARDS, Acute respiratory distress syndrome; OR, Operating room; VSD, Ventricular septal defect; PPE, Personal protective equipment; ASD, Atrial septal defect; POD, Post-operative day; ICU, Intensive care unit; CRP, C-reactive protein.

* Corresponding author. Department of Anesthesiology, Critical Care and Pain Medicine, Boston Children's Hospital, 300 Longwood Avenue, Boston, MA, 02115, USA.

** Corresponding author. Department of Anesthesiology, Critical Care and Pain Medicine, Cardiac Anesthesia Division, Boston Children's Hospital, 300 Longwood Avenue, Boston, MA, 02115, USA.

E-mail addresses: Robert.Shaw3@childrens.harvard.edu (R. Shaw), koichi.yuki@childrens.harvard.edu (K. Yuki).

<https://doi.org/10.1016/j.epsc.2020.101495>

Received 24 April 2020; Received in revised form 11 May 2020; Accepted 12 May 2020

Available online 18 May 2020

2213-5766/© 2020 The Authors.

Published by Elsevier Inc.

This is an open access article under the CC BY-NC-ND license

(<http://creativecommons.org/licenses/by-nc-nd/4.0/>).

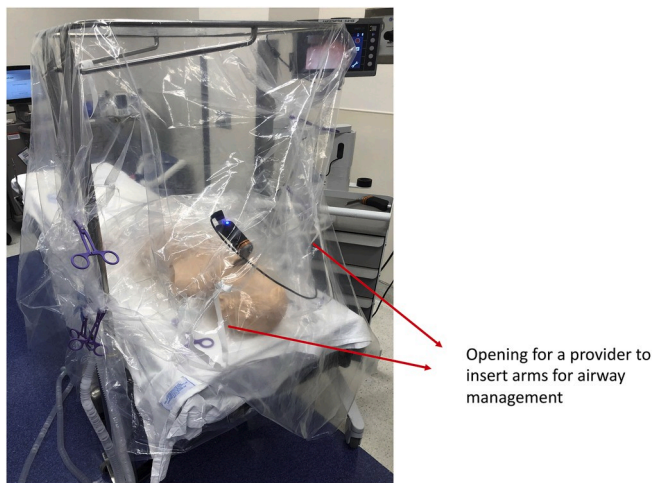


Fig. 1. Plastic barrier for intubation.

radiographic evidence of atelectasis was managed with BiPAP (Fig. 2). On POD #4, he was febrile to 40.0°C and remained BiPAP-dependent. Screening cultures for bacterial infection were sent, along with nasopharyngeal swab for respiratory virus PCR panel including SARS-CoV-2, which resulted positive.

Throughout his intensive care unit (ICU) course, respiratory support was de-escalated from BiPAP to high flow nasal cannula, while chest radiographs and inflammatory markers were followed (Figs. 2–3). Complete heart block requiring synchronized ventricular pacing persisted. Permanent pacemaker placement was scheduled on POD #11. To minimize the spread of viral particles during the transport to the OR, the patient was transitioned to low flow nasal cannula and surgical mask after premedications in ICU. All providers involved in the patient's care were in full PPE.

In the OR, the patient's upper body was placed into a department-manufactured aerosol barrier for intubation constructed with several sheets of plastic draping over a Mayo stand, which allowed the

intubating practitioner to be the sole provider needed to access the patient. All intubating equipment was placed inside the drapes along with the anesthesia circuit. The patient was preoxygenated and induced intravenously. The patient was masked with a two-hand technique to enable optimal seal and bagged by the assistant. Rapid sequence dose of rocuronium was administered. Once relaxation through neuromuscular blockade was achieved, anesthesia machine flows were turned off, and the patient was intubated using video laryngoscopy. After the endotracheal tube was visualized to pass through the glottis, the intubating provider inflated the cuff and the anesthesia circuit was attached. Endotracheal tube position was confirmed via visualized chest rise along with end-tidal CO₂ tracing, before the endotracheal tube was briefly clamped and an in-line suction catheter was added. A HEPA filter was attached proximal to the sampling line in the circuit to assure adequate viral filtering. Throughout the case, the patient received inotropic support with dopamine, and remained hemodynamically stable with adequate respiratory gas exchange. The patient was transported back to the ICU intubated. He was extubated on the following day to BiPAP. He was transitioned to high flow nasal cannula for two additional days, then to low flow nasal cannula. The patient was discharged home with no supplemental oxygen requirement on POD #19.

3. Discussion

Existing literature describes patient screening, triage for surgery and techniques to mitigate dissemination and contamination of the virus [1–3]. Our patient presented issues related to preoperative testing and timing of urgent surgery outside of the scope of previous reports.

3.1. Preoperative COVID-19 testing in pediatric patients

As the percentages of pediatric COVID-19 patients in China, Italy and US were 2%, 1.2% and 1.7%, respectively [4], SARS-CoV-2 seems less prevalent in children. The case-fatality rate of pediatric population was low (0–0.2%) in both China and Italy, indicating that children generally suffered from less severe disease. Our patient was asymptomatic at the time of initial surgery. Although our center has instituted routine,

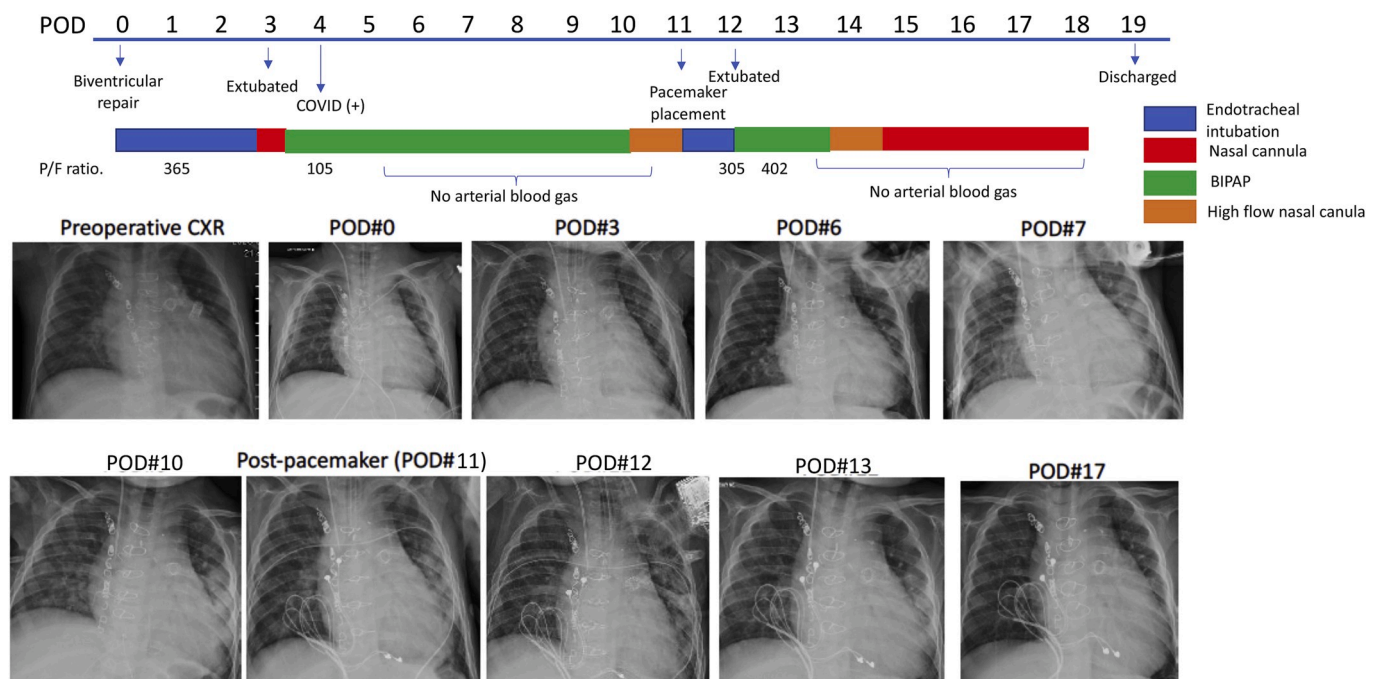


Fig. 2. Clinical course of the patient and serial chest X-rays. The clinical course of the patient including respiratory status was shown. POD, postoperative day; P/F ratio, PaO₂/FiO₂ ratio.

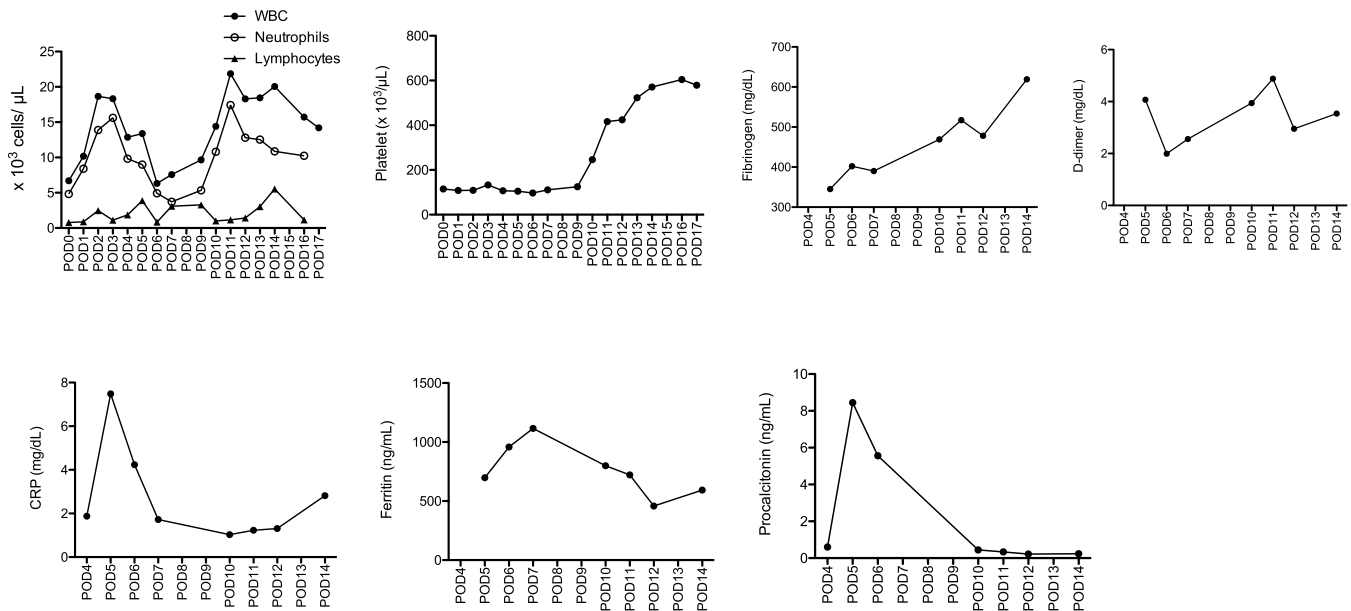


Fig. 3. Inflammatory marker profiles of the patient. White blood cell (WBC), neutrophil, lymphocyte, platelet counts along with fibrinogen, D-dimer, CRP, ferritin, and procalcitonin levels were plotted throughout his hospital stay.

pre-operative SARS-CoV-2 testing now, this was not established at the time of his biventricular repair. Viral testing was obtained one day after extubation on POD#4, due to fever and worsening respiratory status. This patient had no documented SARS-CoV-2 exposure. With an incubation period of 2–14 days, it is highly possible that the patient was infected prior to the surgery. Many patients with palliated congenital heart disease have respiratory symptoms at baseline, making it difficult to reliably differentiate COVID-19-related symptoms from cardiac-related symptoms. Routine testing might address this concern.

3.2. Timing of urgent surgery

Post-operative complete heart block without reliable escape junctional or ventricular rhythm meant this patient was completely dependent on temporary pacing. The threshold of temporary pacing leads can increase over time, permanent pacemaker implantation usually occurs within two weeks of initial surgery. Our patient was symptomatic with severe COVID-19 disease [5]. Elective surgery is usually postponed in the setting of active infection, but the timing of surgery was complicated by the temporary nature of current pacing strategy against evidence of ongoing inflammation with the concern that additional stress may potentially worsen viral illness.

A number of laboratory markers have been associated with severe COVID-19 diseases in adult patients. Lymphocyte count $<1.0 \times 10^3/\mu$ L was associated with the development of ARDS and ICU care [6,7]. The reduction of blood lymphocytes is likely due to their recruitment of T cells to the lung and lymphocyte apoptosis by inflammatory mediators.

In patients with COVID-19, the general inflammatory marker, C-reactive protein (CRP) >1 mg/dL was documented in more severe disease [8], and CRP >5 mg/dL was associated with ARDS development [5]. Our patient's CRP peaked at 7.48 mg/dL on POD#5.

Ferritin is a shell protein that sequesters iron in its core. Macrophages secrete intracellular ferritin into circulation during inflammation [9]. Serum ferritin >300 ng/mL has been associated with ARDS development and death [6,10]. Our patient's ferritin peaked at 1116 ng/mL on POD#7. Procalcitonin is a precursor of calcitonin and induced during inflammation by lipopolysaccharide from microbes and mediators such as TNF- α and IL-6 [11]. Procalcitonin >0.5 ng/mL was associated with severe COVID-19 disease [7,8]. Our patient's procalcitonin peaked at

8.45 ng/mL on POD#5 and decreased to 0.45 ng/mL on POD#10.

D-dimer, a metabolite of cross-linked fibrin is often a marker of thrombosis but is also induced during inflammation. D-dimer >0.5 mg/dL and >1 mg/dL at admission was associated with more severe disease and death, respectively in COVID-19 positive adults [7,10]. Optimal timing of surgical implantation of permanent pacemaker was considered by judging whether the peak of severity had passed. D-dimer was increasing on POD#10–11, but the other inflammatory markers were improving in keeping with his clinical course, which led us to proceed surgery on POD#11. The endothelium, which regulates coagulation, expresses ACE2 – a target protein for SARS-CoV-2. Increased D-dimer was in parallel with an increase in platelet and fibrinogen levels, suggesting that the patient was in a procoagulant state as reported in a subset of COVID-19 patients [12]. The increase of these markers might represent healing process of the endothelium rather than ongoing damage. This hypothesis needs future investigation.

3.3. Perioperative management of children with COVID-19

Details of perioperative PPE for COVID-19 are well described by others [1–3]. Briefly, we used our checklist for COVID-19 case. Preoperative discussion by members involved in the case occurred in the days before surgery and reviewed in the immediate pre-intervention period. The surgical case was undertaken in a dedicated COVID-19 operating room under full PPE. Intubation was performed within the plastic barrier (Fig. 1) to mitigate the degree of dissemination of viral particles during the intubation.

4. Conclusion

We describe the complicated decision-making process of timing of surgical intervention for a child with symptoms consistent with severe COVID-19. Multi-disciplinary input into decision-making of procedure timing, comprehensive utilization of PPE, pre-emptive planning and simulation of the sequence of procedure from in-ICU to induction of anesthesia and intubation-ventilation in the operating room ensured the best procedural outcome for patient while minimizing aerosolization and exposure to treating healthcare workers.

Financial disclosure

This work was in part funded by NIH R21HD099194 (K.Y.)

Consent

Obtained from the patient's parent (legal guardian).

Declaration of competing interest

The authors declare that they have no known competing financial interests or personal relationships that could have appeared to influence the work reported in this paper.

CRediT authorship contribution statement

Robert Shaw: Writing - original draft. **Nathaniel Tighe:** Writing - review & editing. **Kirsten C. Odegard:** Writing - review & editing. **Peta Alexander:** Writing - review & editing. **Sitaram Emani:** Writing - review & editing. **Koichi Yuki:** Writing - original draft, Writing - review & editing.

Acknowledgement

We thank Mr. Ye Lee and Ms. Antonnia Kelly (both Boston's Children's Hospital) for the assist of the case.

References

- [1] Li W, Huang J, Guo X, Zhao J, Mandell MS. Anesthesia management and perioperative infection control in patients with the novel coronavirus. *J Cardiothorac Vasc Anesth* 2020.
- [2] Matava CT, Kovatsis PG, Summers JL, et al. Pediatric airway management in COVID-19 patients – consensus guidelines from the Society for pediatric anesthesia's pediatric difficult intubation collaborative and the Canadian pediatric anesthesia society. *Anesth Analg* 2020.
- [3] Wen X, Li Y. Anesthesia procedure of emergency operation for patients with suspected or confirmed COVID-19. *Surg Infect (Larchmt)* 2020;21(3):299.
- [4] Yuki K, Fujiogi M, Koutsogiannaki S. COVID-19 pathophysiology: a review. *Clin Immunol* 2020.
- [5] Dong Y, Mo X, Hu Y, et al. Epidemiology of COVID-19 among children in China. *Pediatrics* 2020.
- [6] Wu C, Chen X, Cai Y, et al. Risk factors associated with acute respiratory distress syndrome and death in patients with coronavirus disease 2019 pneumonia in Wuhan, China. *JAMA Intern Med* 2020.
- [7] Huang C, Wang Y, Li X, et al. Clinical features of patients infected with 2019 novel coronavirus in Wuhan, China. *Lancet* 2020;395(10223):497–506.
- [8] Guan WJ, Ni ZY, Hu Y, et al. Clinical characteristics of coronavirus disease 2019 in China. *N Engl J Med* 2020.
- [9] Kernan KF, Carcillo JA. Hyperferritinemia and inflammation. *Int Immunol* 2017;29(9):401–9.
- [10] Zhou F, Yu T, Du R, et al. Clinical course and risk factors for mortality of adult inpatients with COVID-19 in Wuhan, China: a retrospective cohort study. *Lancet* 2020;395(10229):1054–62.
- [11] Vijayan AL, Vanimaya, Ravindran S, et al. Procalcitonin: a promising diagnostic marker for sepsis and antibiotic therapy. *J Intensive Care* 2017;5:51.
- [12] Ranucci M, Ballotta A, Di Dedda U, et al. The procoagulant pattern of patients with COVID-19 acute respiratory distress syndrome. *J Thromb Haemostasis* 2020.